



CASE REPORT

Management of Traumatic Injury in Maxillary Teeth using EndoSequence: A Cone Beam Computed Tomography Case Report

Richa Nanray

ABSTRACT

Teeth affected with necrosis, apical periodontitis, large periapical lesion, external resorption, open apex require definitive endodontic therapy in addition to excellent biocompatible tricalcium silicate cement for root repair and regeneration of the periodontium. Mineral trioxide aggregate (MTA) has shown superior prognostic results in the mentioned procedures due to its sealing ability and antibacterial properties. However, certain major drawbacks with MTA are its long setting time, further discoloration of the tooth structure, and difficulty in handling.

EndoSequence root repair material (Brasseler, USA) is a recently introduced bioceramic. Several clinical and research studies have shown comparable sealing ability of MTA and EndoSequence in apexification and surgical procedures. Presented here is the successful management of a patient whose maxillary anteriors showed destruction of the periapical tissue. Surgical procedure was performed in right central and lateral incisors along with root-end filling with EndoSequence and apexification in left central incisor with placement of an apical plug of EndoSequence. Follow-up radiographs and 12-month cone beam computed tomography (CBCT) showed formation of bony trabeculae surrounding the apical region and intact lamina dura. Based on the clinical report, it appears that EndoSequence is the new root repair material that is user-friendly for the clinician even in the most challenging situations.

Keywords: Apexification, Cone beam computed tomography, EndoSequence, Periapical lesion, Trauma.

How to cite this article: Nanray R. Management of Traumatic Injury in Maxillary Teeth using EndoSequence: A Cone Beam Computed Tomography Case Report. *J Contemp Dent* 2018;8(1):45-49.

Source of support: Nil

Conflict of interest: None

INTRODUCTION

Traumatic injuries to anterior teeth frequently occurring during root development stage can go unnoticed causing

pulp necrosis, leading to serious complications, such as immature tooth with open apex. Multiple adjoining teeth can also be traumatized causing periapical pathology, root resorption requiring necessary endodontic treatment for limiting infection, preventing further periodontal tissue breakdown and promoting regeneration of the tissues. Managing the complex situation is a challenge for the clinician. Among the treatment options, revascularization has comparable but not superior treatment outcome to apexification for root-end closure of immature permanent teeth.¹

Apexification procedures aim at inducing apical root-end closure of immature teeth for favorable obturation. The MTA has been confirmed to create a mineralized barrier successfully in long-term clinical and radiographic evaluation.² However, insertion of an apical plug of MTA at the root end is difficult because to place the MTA carrier within the canal, larger and more round preparation of the canal is required, resulting in further thinning of the walls.

EndoSequence (Endosequence BC RRM-Fast Set Putty, Brasseler USA) (Fig. 1) is a newly introduced tricalcium-based silicate cement with vast majority of clinical and research studies comparing it with MTA.³ It is a nanoparticulate premixed bioceramic formulation in syringeable and putty form that provides easy handling and application.

Comparative analysis with MTA showed comparable marginal adaptation during apexification of open apices together with comparable mechanical and biological properties.^{3,4} It is hydrophilic, insoluble, radiopaque, aluminum-free and pH of the tricalcium silicate-based cement is 12 at all time intervals.⁵

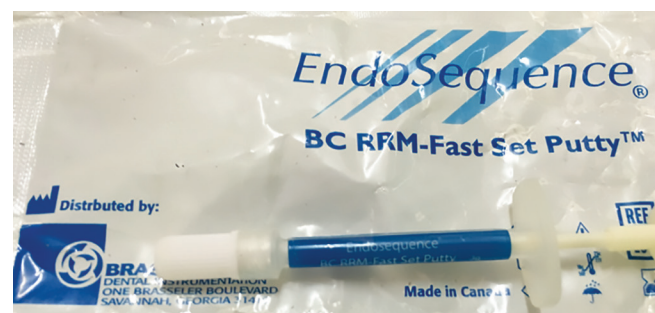

Fig. 1: EndoSequence material

Dental Surgeon

Department of Conservative Dentistry and Endodontics, Shri Bankey Bihari Dental College and Research Centre, Ghaziabad Uttar Pradesh, India

Corresponding Author: Richa Nanray, Dental Surgeon Department of Conservative Dentistry and Endodontics Shri Bankey Bihari Dental College and Research Centre, Ghaziabad Uttar Pradesh, India, Phone: +919971790288, e-mail: richu1090@gmail.com

It is characterized by the release of calcium hydroxide in solution forming hydroxyapatite in contact with tissue fluids. Scanning electron microscopy and phase analysis of the hydrated cement were composed of a cement phase, exhibiting elemental peaks for calcium, silicon, and oxygen and a radiopacifier phase of tantalum oxide.⁵ Furthermore, recently, in a study of the osteogenic potential of EndoSequence by Rifaey et al,⁶ it was stated that it promotes osteoblast differentiation better than MTA, resulting in active bone formation in teeth associated with large periapical lesions.

It can be thus used for regenerative endodontic procedures, as its mineralization inductive capacity stimulated odontoblastic differentiation and mineralization nodule formation by activating the mitogen-activated protein kinases pathway as did MTA.^{6,7} Scientific research provides valuable insights into the mechanism of bioceramic-mediated antiosteoclastogenic activity, confirming its bioactivity to promote bone formation.⁸

Presently developed bioaggregate EndoSequence has been effectively used in various clinical applications for root repair, showing promising clinical results. A clinical microsurgery suggests that it is a suitable root-end filling material to be used in endodontic surgery.⁹

Inflammatory external resorption as a sequela to trauma requires disinfection protocol to remove causative bacteria. Current scientific evidences support the ability of $\text{Ca}(\text{OH})_2$ to destroy bacteria in the main portion of the canal and prevent growth of bacteria within the dentinal tubules, noninstrumented sites of the root canal. $\text{Ca}(\text{OH})_2$ decreased the number of *Enterococcus faecalis* at all depths within the dentinal tubules within 24 hours.¹⁰ Adequate disinfection with calcium hydroxide and EndoVac using NaOCl 5.25% and surgical curettage of the periapical lesion along with an effective root-end sealing material has proved beneficial in challenging situations with associated root resorption.¹¹

Presented here is a case of untreated injury to the permanent anteriors 7 years back, causing periapical pathology, external root resorption, necrotic immature tooth with apical periodontitis, and their subsequent management. The girl wanted to get her discolored teeth and undesirable esthetic smile corrected.

CASE REPORT

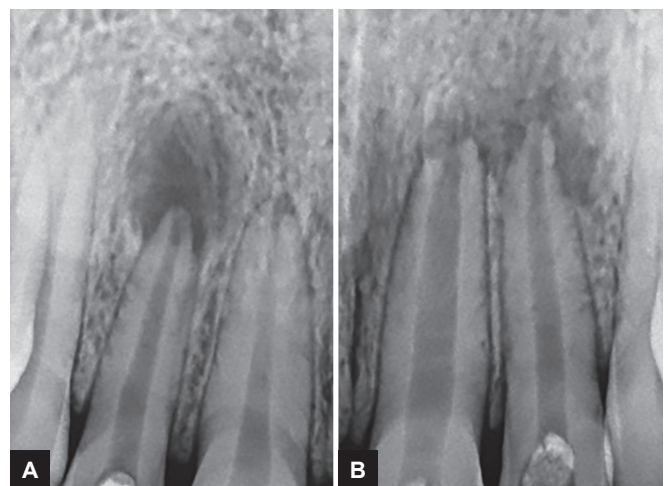
A 17-year-old female reported to the department complaining of painful, fractured, and discolored anterior teeth. She gave a history of accidental trauma to her maxillary anteriors 7 years back, causing intermittent discomfort but have now become painful since the last 5 months. An intraoral examination revealed that the left central incisor was discolored and both central and

right lateral were fractured (Fig. 2). All four anterior teeth tested nonvital to vitality testing and were firm. Preoperative radiographic examination revealed the presence of a well-defined radiolucency apical to the right lateral incisor extending mesiodistally more than 10 mm in diameter. However, the right central incisor showed signs of mild external resorption and radiolucency around its root apex. Left central incisor showed immature root formation with a large canal, widening of lamina dura, and bony rarefaction extending to the root of lateral incisor (Fig. 3) and was also confirmed in CBCT analysis. Her medical history was noncontributory.

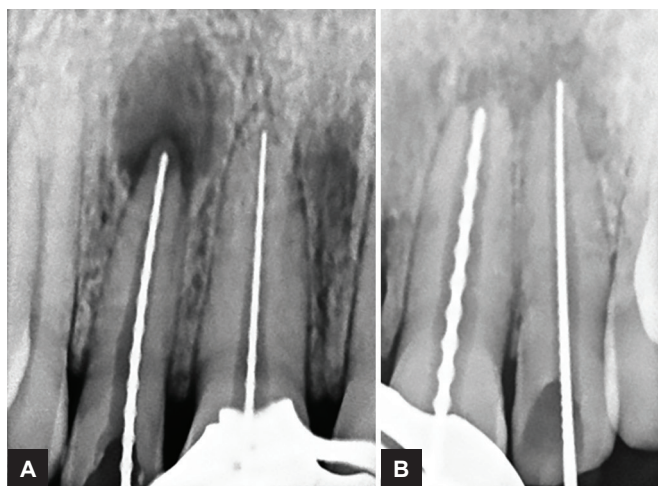
Based on examination and radiographic findings, a diagnosis of periapical abscess with 11, external resorption with 12, an open apex with 21, and apical periodontitis with 22 after a sequela of trauma was made. Due to pulp necrosis involving multiple teeth causing considerable periodontal destruction, restoring the healthy condition of teeth and surrounding bone was a challenging situation for an endodontist. With patient's informed consent, it was decided to perform surgical apicoectomy of 11, 12 with EndoSequence root-end filling along with

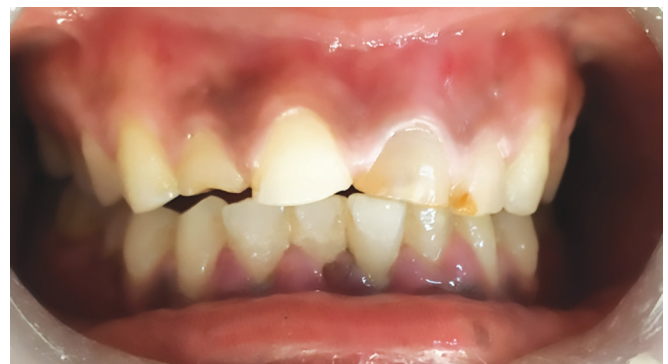

Fig. 2: Preoperative photograph



Figs 3A and B: Preoperative radiograph showing large periapical lesion w.r.t. 12 and root resorption in 11. Blunderbuss canal w.r.t. 21 and periapical lesion involving 22



Figs 4A and B: Working length estimation

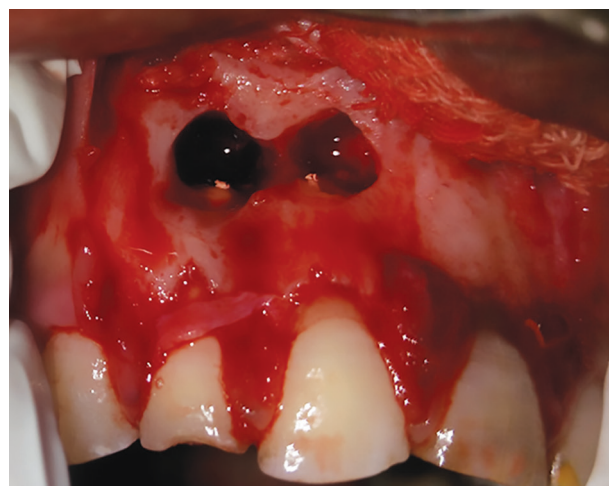

Fig. 5: Apicoectomy procedure showing flap retraction and root apices of 11 and 12

nonsurgical apexification of 21 to achieve an apical seal followed by conventional root canal treatment in 22. Patient was informed of fair and predictable prognosis as teeth were firm with normal marginal gingiva.

Treatment was initiated promptly to prevent further hard tissue loss with ideal access cavity preparation in all four incisors under rubber dam isolation (Coltene Hygenic) and local anesthesia. After determining the working length (Fig. 4) with # 15 K file w.r.t 11, 12, 22, and 40 K file (MANI resources company Ltd, Japan) w.r.t 21, cleaning and shaping of the root canals were started with hand K files along with alternate irrigation with 3% NaOCl (Chemodent Pvt. Ltd) and saline using EndoVac (Discus Dental, culver city, CA) irrigation system. Calcium hydroxide was used as an intracanal dressing to facilitate healing of the tissues and disinfection of the canals and temporized.¹¹ Systemic antibiotics and analgesics were prescribed for a week.

After a week, the patient was asymptomatic, so bio-mechanical preparation was continued till no. 45 K-file in 11, 12, 22 using the step-back technique. In 21, using circumferential technique, preparation was slowly done till 70 K file. Calcium hydroxide medicament was placed in all four teeth and again repeated after 2 weeks to attain disinfection. Intraoral periapical (IOPA) radiographs were repeated at every visit to assess the progress of the procedure. Then, obturation was done in 11 and 12 using gutta-percha and AH Plus sealer (Dentsply Ltd) by lateral condensation technique.

For the apexification procedure in 21, the canal was dried with absorbent paper points and an apical plug of 3 to 5 mm was placed with EndoSequence fast set putty and condensed lightly with hand pluggers (Dentsply Ltd) to allow the formation of a proper apical seal. The packable consistency and viscosity allowed it to be adapted properly to the walls of the canal that was radiographically

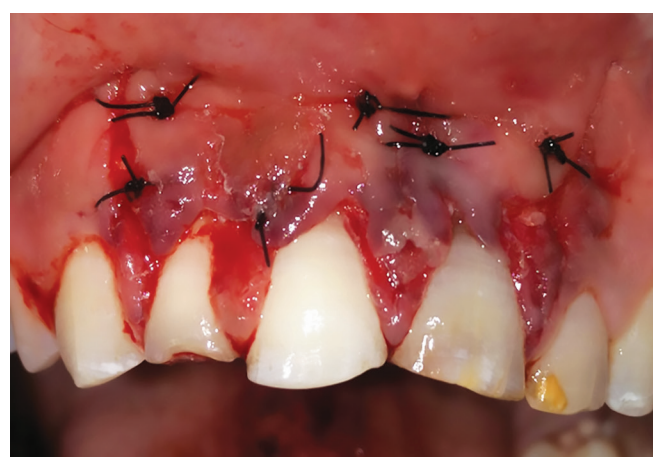

Fig. 6: Suture placement

confirmed. There was no extrusion of the apical plug as seen in the IOPA radiograph.

Prior to surgery, consent was taken with complete hemogram and blood coagulation report being normal. Under local anesthesia, a full thickness mucoperiosteal flap was elevated from canine to canine. A large soft tissue lesion was seen involving the root apices of 11, 12. It was circumferentially separated from the bony crypt and teeth using Gracey curettes (API). The surgical site was washed with sterile saline solution after complete removal (Fig. 5).

Root apices of 11, 12 were resected obliquely with the help of round bur. And then, retro cavity was prepared with small round bur till 2 mm depth and the EndoSequence putty material was filled in the prepared cavity, sealing both the apices. The mucoperiosteal flap was sutured in place (Fig. 6) and retrograde filling accuracy was confirmed radiographically (Fig. 7). During the subsequent appointment, canal of 21 was back-filled using AH Plus sealer and injectible thermoplasticized gutta-percha and access cavity was sealed with composite.

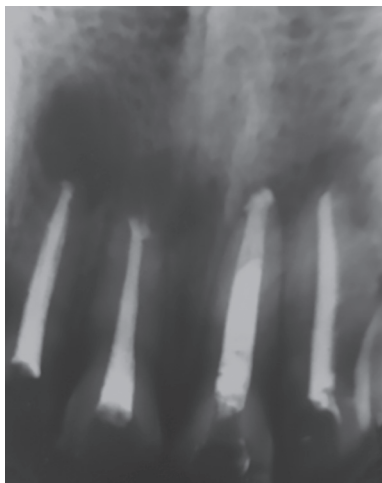


Fig. 7: Postsurgical IOPA radiograph

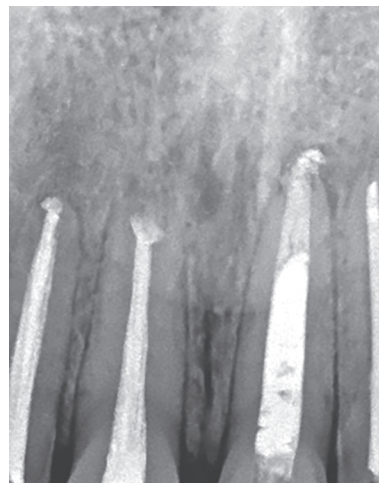
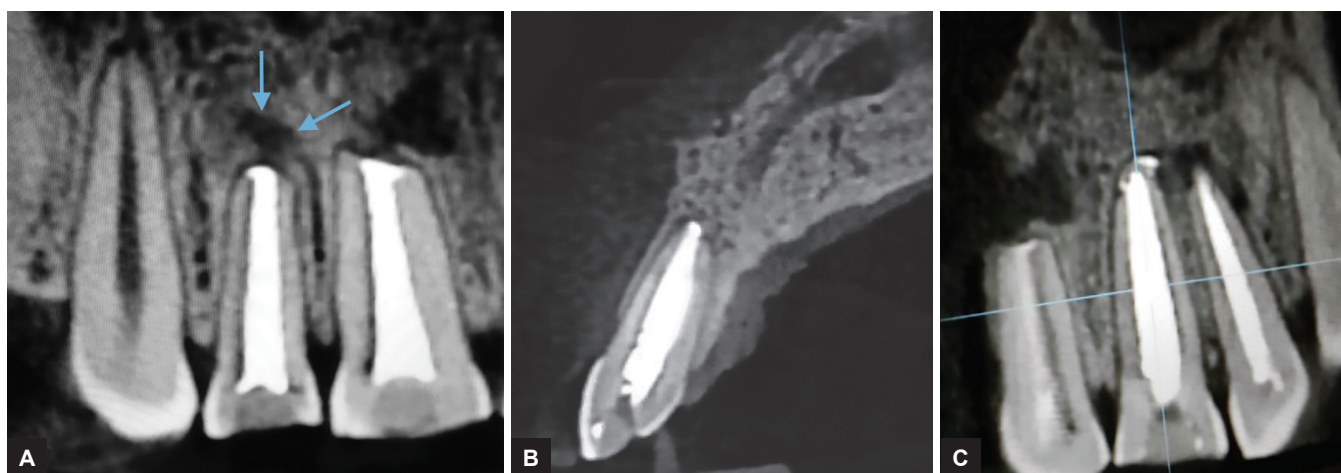


Fig. 8: Ten-month follow-up



Figs 9A to C: CBCT images showing Endosteal new bone trabeculae along the margins of the lesion indicating bone formation in 11 and 12, intact lamina dura, periodontal spaces in 21, 22, reduction of the periapical lesion

Clinically, the patient was asymptomatic during follow-up assessment. Radiographically, healing was observed as there was regression of the periapical lesion as compared from preoperative radiographic assessment associated with right central and lateral incisor. Initiation of root-end closure could also be detected in the left central incisor with considerable apical healing. At 12-month follow-up, normal sulcular probing depth and function were observed. A 10-month follow-up revealed osseous healing surrounding the apices of all four incisors with intact lamina dura (Fig. 8).

A CBCT analysis was carried out at the 12-month follow-up to assess the bony condition of the periradicular area (Fig. 9). The report confirmed that the periodontal ligament spaces were intact. Endosteal new bone trabeculae could be noted along the proximal and palatal margins of the lesion in 12 and 11. In 21, slight periapical extrusion of the apical plug can be seen, but the lamina dura appears intact, suggesting healing periapical lesion. The bony rarefaction involving 21 and 22 has also been

reduced considerably, suggesting that the presence of the extruded material was accepted to the apical tissues undergoing healing.

DISCUSSION

Teeth subjected to immature root development, necrotic pulps with periapical bone loss, and root resorption present multiple challenges for successful endodontic treatment. Evidence suggests that MTA apexification may be more beneficial for severely injured teeth than a regenerative endodontic procedure. Apexification using EndoSequence fast setting putty can be easily placed with apical sealing ability that prevents any leakage and favors regeneration.

Endodontic treatment followed by apical surgery of periapical lesions more than 10 mm in diameter can provide assured biological healing of the osseous defect and regeneration of periodontal tissue.¹² Successful results of conventional endodontic surgery have been reported in about 40 to 90% of cases.¹³

An alternative material to MTA with improved handling properties is a newly developed EndoSequence root repair material possessing antibacterial activity during its setting reaction due to its highly alkaline pH. It possesses antibacterial properties against *E. faecalis* strains recovered from root canal infections as investigated by Lovato, and causes osteoblast differentiation in mesenchymal stem cells, suggesting its use as root-end filling material.

Due to its clinical advantages of superior biocompatibility, effective sealing capability, and the ability to improve regeneration of the peripheral root tissues, EndoSequence is comparable to other root-end filling materials favoring osteogenic activity of bone and preventing any further influx of bacteria.¹⁴

The preferred treatment option of external resorption aims at bacterial disinfection of the root canal space to kill bacteria and neutralize the endotoxins that are inflammatory stimulators. A properly filled canal with calcium hydroxide reduces the microbial host interaction in the periapex to the minimum due to its antibacterial effect and alkaline pH as recommended by Heithersay.¹⁵

With patient cooperation and recommended procedures from available scientific data, it was possible to gain osseous healing and restore function and health of the dentition.

CONCLUSION

Successfully sealing the wide open canal laterally and apically is challenging. Thus, the choice of a root repair material that can be easily handled and placed within the confines of the canal is important for the clinician. EndoSequence can be used as an alternative to MTA due to its superior biological properties, physical, and clinical performance.^{16,17}

Radiographically, osseous regeneration of the pathosis was evident and the patient was pleased with the treatment outcome.

REFERENCES

1. Alobaid AS, Cortes LM, Lo J, Nguyen TT, Albert J, Abu-Melha AS, Lin LM, Gibbs JL. A pilot retrospective cohort study. *J Endod* 2014 Aug;40(8):1063-1070.

2. Bücher K, Meier F, Diegritz C, Kaaden C, Hickel R, Kühnisch J. Long-term outcome of MTA apexification in teeth with open apices. *Quintessence Int* 2016 Mar;47(6):473-482.
3. Tran D, He J, Glickman GN, Woodmansey KF. Comparative analysis of calcium silicate-based root filling materials using an open apex model. *J Endod* 2016 Apr;42(4):654-658.
4. Memiş Özgül B, Bezgin T, Şahin C, Sarı Ş. Resistance to leakage of various thicknesses of apical plugs of Bioaggregate using liquid filtration model. *Dent Traumatol* 2015 Jun;31(3):250-254.
5. Grech L, Mallia B, Camilleri J. Characterization of set intermediate restorative material, biodentine, bioaggregate and a prototype calcium silicate cement for use as root-end filling materials. *Int Endod J* 2013 Jul;46(7):632-641.
6. Rifaey HS, Villa M, Zhu Q, Wang YH, Safavi K, Chen IP. Comparison of the osteogenic potential of mineral trioxide aggregate and endosequence root repair material in a 3-dimensional culture system. *J Endod* 2016 May;42(5):760-765.
7. Jung JY, Woo SM, Lee BN, Koh JT, Nör JE, Hwang YC. Effect of biodentine and bioaggregate on odontoblastic differentiation via mitogen-activated protein kinase pathway in human dental pulp cells. *Int Endod J* 2015 Feb;48(2):177-184.
8. Zhang J, Zhu L, Yan P, Peng B. Effect of bioaggregate on receptor activator of nuclear factor-kappa B ligand-induced osteoclastogenesis from murine macrophage cell line *in vitro*. *J Endod* 2015 Aug;41(8):1265-1271.
9. Shinbor N, Grama AM, Patel Y, Woodmansey K, He J. Clinical outcome of endodontic microsurgery that uses endosequence BC root repair material as the root-end filling material. *J Endod* 2015 May;41(5):607-612.
10. Fuss Z, Tsesis I, Lin S. Root resorption—diagnosis, classification and treatment. choices based on stimulation factors. *Dent Traumatol* 2003 Aug;19(4):175-182.
11. Mohammadi Z, Shalavi S, Yazdizadeh M. Antimicrobial activity of calcium hydroxide in endodontics: a review. *Chonnam Med J* 2012 Dec;48(3):133-142.
12. Kim S, Kratchman S. Modern endodontic surgery concepts and practice: a review. *J Endod* 2006 Jul;32(7):601-623.
13. Zuolo ML, Ferreira MO, Gutmann JL. Prognosis in periradicular surgery: a clinical prospective study. *Int Endod J* 2000 Mar;33(2):91-98.
14. Alanxi AZ, Jiang J, Safavi KE, Spangberg LS, Zhu Q. Cytotoxicity evaluation of endosequence root repair material. *Oral Surg Oral Med Oral Pathol Oral Radiol Endod* 2010 Mar;109(3):e122-e125.
15. Heithersay ZS. Calcium hydroxide in the treatment of pulpless teeth with associated pathology. *J Br Endo Soc* 1975;8:74-93.
16. Lovato KE, Sedgley CM. Antibacterial activity of endosequence root repair material and ProRoot MTA against clinical isolates of *Enterococcus faecalis*. *J Endod* 2011 Nov;37(11):1542-1546.
17. Nasseh AA. Dental tribune Middle East & Africa Edition. A combined surgical and non-surgical approach to repair an external root resorption utilizing a nano-particulate bioceramic root repair material. *Endod Pract* 2015 Sep-Oct.