



## CASE REPORT

# Esthetic Rehabilitation of a Fractured Permanent Maxillary Central Incisor by Reattachment

<sup>1</sup>Saimanaaz Abdul Hakeem Shaikh, <sup>2</sup>Vanitha U Shenoy, <sup>3</sup>MV Sumanthini, <sup>4</sup>Ritesh B Pawar

## ABSTRACT

Crown fractures of the anterior teeth are a common form of dental trauma mainly affecting children and adolescents. One of the options for managing crown fractures is the reattachment of the fractured fragment when the tooth fragment is available with minimal or no violation of the biological width. Reattachment of fractured fragments can provide good esthetics, as it maintains the tooth's original anatomic form, color, and surface texture. It also restores function and is a relatively simple procedure. This case report deals with the esthetic management of a crown-root fracture that was successfully treated with endodontic treatment followed by reattachment of fractured fragment with fiber post.

**Keywords:** Coronal fracture, Dental trauma, Fiber post, Reattachment.

**How to cite this article:** Shaikh SAH, Shenoy VU, Sumanthini MV, Pawar RB. Esthetic Rehabilitation of a Fractured Permanent Maxillary Central Incisor by Reattachment. J Contemp Dent 2016;6(1):52-56.

**Source of support:** Nil

**Conflict of interest:** None

## INTRODUCTION

Traumatic tooth fractures are the common reason for seeking dental care. Most dental injuries occur between 2 and 3 years and between 8 and 12 years of age being more common in boys than in girls because boys are actively involved in extracurricular activities.<sup>1,2</sup> The most frequent causes of trauma are falls; bicycle, motorcycle, and car accidents; sports activities; collision with other people and objects; and domestic violence fights and physical assault.<sup>3,4</sup>

Coronal fractures of permanent incisors represent 18 to 22% of all trauma to dental hard tissues, 28 to 44% being simple (enamel and dentin), and 11 to 15% complex (enamel, dentin and pulp). Of these, 96% involve

maxillary central incisors.<sup>5</sup> Chosack and Eildeman published the first case report on reattachment of a fractured incisor fragment in 1964.<sup>6</sup> Tennery<sup>7</sup> was the first to report the reattachment of a fractured fragment using acid-etch technique. Subsequently, Simonsen<sup>8</sup> has reported similar cases.

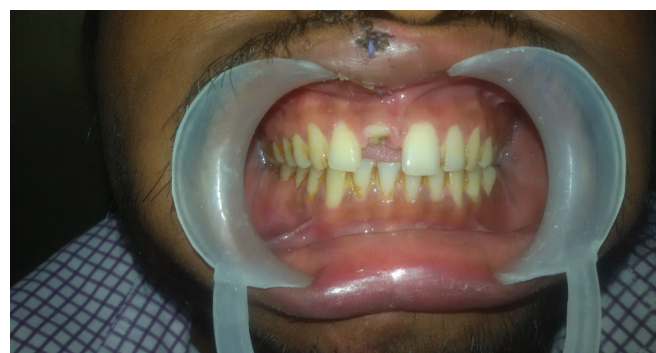Reattachment of tooth fragments should be the first choice and is a viable alternative to conventional approach with minimal or without violation of biologic width because of simplicity, natural esthetics, and conservation of tooth structure. This case report deals with the management of a fractured permanent maxillary central incisor by coronal fragment reattachment using a fiber post.

## CASE REPORT

A 28-year-old male patient reported to the Department of Conservative Dentistry and Endodontics with a history of fall and injury to the upper front teeth 2 days prior. Patient was symptomatic. Medical history was not contributory.

Clinical examination (Fig. 1) revealed horizontal fracture with the right maxillary central incisor (11) involving enamel, dentin, and pulp extending labio-palatally. The fractured fragment was loosely attached on the palatal aspect to the tooth. Extraoral examination revealed no significant abnormalities. Soft tissue examination revealed laceration of the upper lip. Tooth was tender on percussion and palpation. Periodontal probing depths were within the normal parameters. The tooth was grade I mobile and gave an early response to vitality tests.

An intraoral periapical radiograph (Fig. 2) showed a thin horizontal radiolucent line approximately at Cementoenamel junction (CEJ). The case was diagnosed

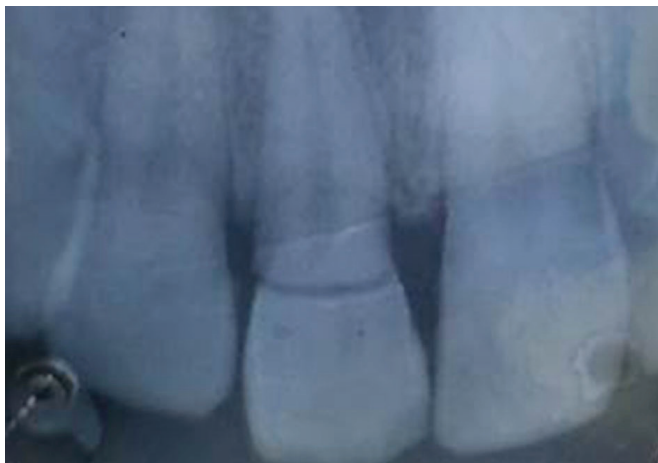

**Fig. 1:** Complicated crown-root fracture with the right maxillary central incisor

<sup>1,4</sup>Postgraduate Student, <sup>2</sup>Head and Professor, <sup>3</sup>Professor

<sup>1-4</sup>Department of Conservative Dentistry and Endodontics  
MGM Dental College and Hospital, Navi Mumbai, Maharashtra  
India

**Corresponding Author:** Saimanaaz Abdul Hakeem Shaikh  
Postgraduate Student, Department of Conservative Dentistry  
and Endodontics, MGM Dental College and Hospital, Navi  
Mumbai, Maharashtra, India, Phone: +8879564175, e-mail:  
drsaimash2787@gmail.com



**Fig. 2:** Intraoral periapical radiograph showing a thin horizontal radiolucent line approximately at CEJ



**Fig. 3:** Fractured segment preserved in saline solution to prevent dehydration and discoloration

as symptomatic irreversible pulpitis secondary to complicated crown root fracture (N502.54, as per WHO classification) with symptomatic apical periodontitis. The patient expressed the desire to maintain the tooth and restore it, as it was economical compared with a fixed partial prosthesis. A detailed explanation about the treatment plan was given to the patient, which included completion of endodontic treatment followed by reattachment of the fractured fragment using a fiber post. An informed consent was taken from the patient.

## MANAGEMENT

**Removal of fractured fragment:** In the first visit, local anesthesia (2%) with adrenaline (1:200,000) (Neon Laboratories Ltd., Mumbai, Maharashtra, India) was administered and the fractured fragment was completely removed atraumatically by gently holding the crown of the involved tooth with an extraction forceps. Hemorrhage was controlled and the fractured segment was preserved in physiological saline solution (Fresenius Kabi AG, Bad Homburg vor der Höhe, Germany) (Fig. 3).

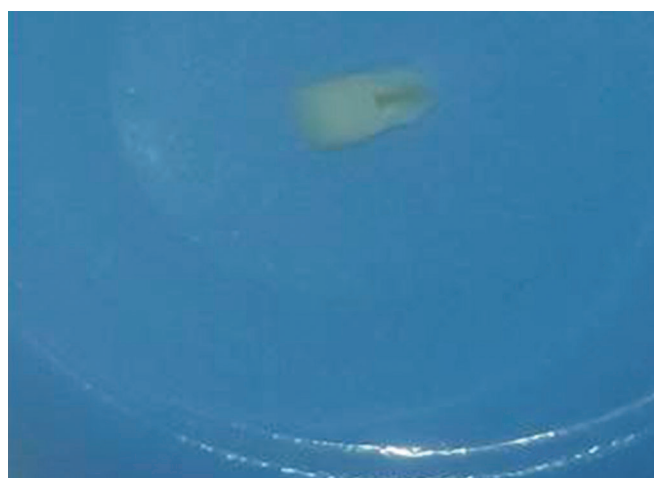
**Treatment of the fractured fragment:** The fit of the fragment was checked; it was observed that there was some hindrance in the approximation palatally; so, after completion of root canal treatment and before trial of post, surgical reflection of palatal flap was planned. A two-stage procedure was decided upon which included completion of endodontic treatment in the first visit and raising of palatal flap and fragment reattachment in the second visit.

The coronal portion of the fractured fragment was immersed in 5% sodium hypochlorite for half an hour and a #20 broach (Mani, INC, Utsunomiya, Tochigi, Japan) was used for complete debridement of pulp tissue in the pulp

chamber. The fragment was rinsed with 0.9% normal saline to remove residual sodium hypochlorite and preserved in normal saline till the end of the procedure. A housing (Fig. 4) was also prepared in the pulp chamber of the fractured crown fragment with a long tapered fissure bur (Mani, Inc, Japan) for receiving the coronal portion of the fiber post.

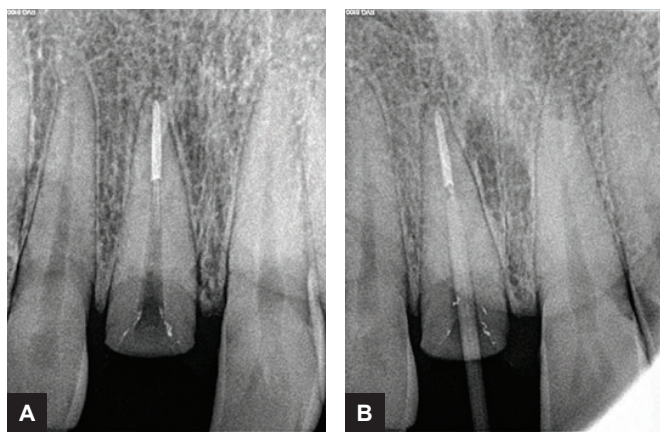
**Treatment of remaining tooth structure:** The root canal was debrided using a #20 broach (Mani, Inc, Japan). Tentative working length was established using an Electronic Apex Locator, Raypex 5 (VDW, München, Germany) and the corrected working length was confirmed by radiograph. Biomechanical preparation was done by a step-back technique. The master apical file (MAF) was 40 K-file (Mani, Inc, Japan). A concentration of 5% sodium hypochlorite and saline (Fresenius Kabi AG, Bad Homburg vor der Höhe, Germany) solution were used as irrigants during the preparation alternately.

The root canal was dried with absorbent points (Sure Endo, Gyeonggi-do, Korea) and obturated using lateral



**Fig. 4:** A housing prepared in the pulp chamber of the fractured crown fragment for receiving the coronal portion of the post





**Figs 5A and B:** (A) Post space preparation and (B) fiber post trial

compaction technique with gutta-percha (Dentsply Maillefer, Ballaigues, Switzerland) and AH plus sealer (Dentsply, India Pvt Ltd., Delhi, India). After completion of the obturation, the root canal was prepared for the post placement (Fig. 5A) by removing the gutta-percha from the coronal two-thirds of the canal with heated instruments and postspace was prepared by peeso reamers (size 2, 3) (Mani, Inc, Japan). An appropriate size fiber post (Luminex, Dentatus AB, Sweden) was selected, and alignment of the coronal fragment was verified clinically and radiographically with the post in place (Fig. 5B). The tooth was temporized and patient was recalled the next day.

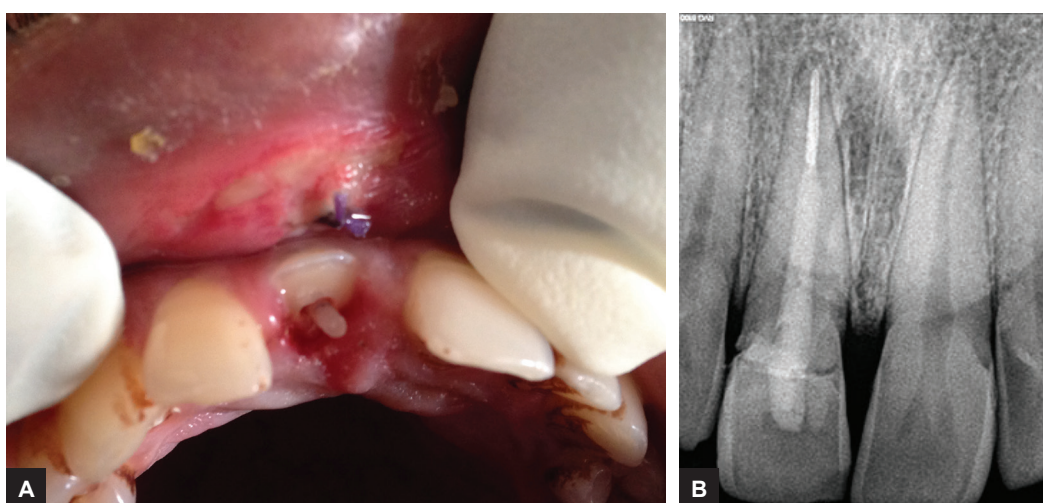
In the second visit, local anesthesia was administered to the patient and a palatal flap (Fig. 6A) was raised by giving a crevicular incision extending from mesial aspect of 12 to mesial aspect of 21 and the alignment of the coronal fragment was verified radiographically with the post in place. Once the post trial was done, the root canal was dried with absorbent points; glass ionomer luting cement (Fuji I, GC, Japan) was placed in the canal with the help of an appropriate size of K-file and was also applied

to the inner side of the housing of the fractured fragment. The fiber post was also coated with the luting cement and along with the coronal segment was cemented in the root canal as one unit (Fig. 6B). The excess cement was removed. Once the cement had set, the flap was sutured in place and a radiograph was taken.

After cementation, the reattachment line was visible labially; thus to mask it, vertical grooves were prepared that would serve as retention locks for the composite resin. A shade A2 was selected as appropriate with the help of VITA shade guide. The area was then etched using 37% phosphoric acid for 15 seconds and thoroughly rinsed off. An adhesive (Adper Single Bond 2, 3M ESPE, St Paul, MN, USA) was applied, cured for 15 seconds following which composite resin (Filtek Z350, 3M ESPE, St Paul, MN, USA) was placed in increments and cured respectively. Finishing and polishing (Sof-Lex disks 3M ESPE, St Paul, MN, USA) of the composite was done and the occlusion was checked (Fig. 7). Patient was given postoperative instructions and advised not to bite or eat with his front tooth. Patient was recalled after 1 week for removal of sutures and final polishing of composite resin restoration.

## DISCUSSION

Coronal fractures must be approached in a methodical and clinically indicated manner to achieve a successful restoration. There are several treatment options for the treatment of tooth fractures involving the biologic width, such as tooth extrusion, crown lengthening followed by fragment reattachment or reconstruction, intentional reimplantation, and even tooth extraction in severe cases.<sup>9</sup> Several conditions must be taken into consideration to determine the ideal option, such as the location and extent of the fracture, the pulpal condition, the degree of tooth eruption, the degree of root formation, and the patient's esthetic demand.<sup>10</sup>



**Figs 6A and B:** (A) Palatal flap with crevicular incision and (B) fracture fragment reattached with fiber post cemented

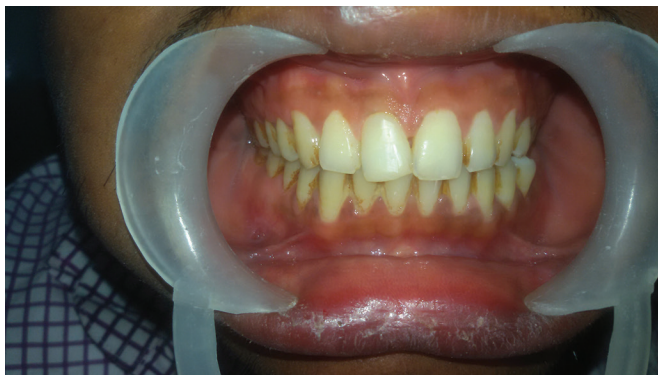

Fig. 7: Fragment reattachment with 11

One of the options for managing coronal tooth fractures, especially when there is no or minimal violation of the biological width, is the reattachment of fractured fragment when it is available.<sup>11</sup> Reattachment of a fragment can provide good esthetics that can be obtained in a single appointment, as this procedure is relatively simple, atraumatic, and inexpensive.<sup>12</sup> With the fracture line extending below the alveolar crestal bone, orthodontic extrusion or surgical extrusion is recommended before the restoration. But with the fracture lying above the alveolar bone crest, reattachment of the fractured fragment is a more viable option. In the present case report, the fracture line seemed to be obliquely running labio-palatally extending below the gingival contour palatally but above the bone crest. Hence, a conservative approach was planned and it was decided to reattach the fractured fragment by fiber post. Hence, for good visualization of the fractured fragment and also to remove the luting cement flash, a palatal flap was raised.

Discoloration and dehydration of the fragment may occur due to longer extraoral time, so in the present case, the fragment was preserved in saline throughout the procedure. In case of complicated fractures when endodontic therapy is required, the space provided by the pulp chamber can be used as an inner reinforcement thus avoiding further preparation of fractured tooth.<sup>13</sup> The use of post increases retention and distributes the stress along the root; with the help of the glass fiber post, the fractured crown can be permanently bonded to the root<sup>14</sup> providing a monoblock effect. Tooth-colored fiber posts have several advantages. They are more esthetic, can be bonded to tooth structure, modulus of elasticity is similar to that of dentin, and hence less chances of fracture.<sup>12</sup> Metal posts are rigid and may cause fracture during tooth movement. In this case, fiber post was used to reinforce the pulp less tooth. Its monoblock effect with no inherent weak interlayer interface helps in distribution of stresses to the remaining radicular dentin; there is less chance of microleakage and good bond strength to tooth.

The remarkable advancement of adhesive systems and resin composites has made reattachment of tooth fragments a procedure that is no longer a provisional restoration, but rather a restorative treatment offering a favorable prognosis. However, this technique can be used only when the intact tooth fragment is available.<sup>8</sup> Although the fractured fragment could be well aligned with the apical fragment, the reattachment line was visible. To mask this line labially and to reinforce the fragments, vertical slots were made across the fractured fragment to aid as retention locks and restored with composite resin to provide a more esthetic appearance.

## CONCLUSION

Tooth fragment reattachment procedure offers conservative, cost-effective, safe, fast, and esthetically pleasing results when the fragment is available. Progress in adhesive technology and composite resin materials allows not only for the creation of esthetic restorations but also for the preservation and reinforcement of tooth structure.

## REFERENCES

1. American Academy of Pediatric Dentistry Council on Clinical Affairs. Guidelines on management of acute dental trauma. *Pediatr Dent* 2008-2009;30:175-183.
2. Santos Filho PC, Quagliatto PS, Simamoto PC Jr, Soares CJ. Dental trauma: restorative procedures using composite resin and mouthguards for prevention. *J Contemp Dent Pract* 2007 Sep 1;8(6):89-95.
3. Andreasen JO, Andreasen FM, Andersson L. Textbook and color atlas of traumatic injuries to the teeth. 4th ed. Copenhagen, Denmark: Blackwell Munksgaard; 2007.
4. Castro JC, Poi WR, Manfrin TM, Zina LG. Analysis of the crown fractures and crown-root fractures due to dental trauma assisted by the Integrated Clinic from 1992 to 2002. *Dent Traumatol* 2005 Jun;21(3):121-126.
5. Pagliarini A, Rubini R, Rea M, Campese M. Crown fractures: effectiveness of current enamel dentin adhesives in reattachment of fractured fragments. *Quint Int* 2000 Feb;31(2):133-136.
6. Chosack A, Eidelman E. Rehabilitation of a fractured incisor using the patient's natural crown- case report. *J Dent Child* 1964;71:19-21.
7. Tennery NT. The fractured tooth reunited using the acid etch bonding technique. *Tex Dent J* 1978 Aug;96(8):16-17.
8. Simonsen RJ. Traumatic fracture restoration: an alternative use of the acid-etch technique. *Quintessence Int* 1979 Feb;10(2):15-22.
9. Wang Z, Heffernan M, Vann WF Jr. Management of a complicated crown root fracture in a young permanent incisor using intentional replantation. *Dent Traumatol* 2008 Feb;24(1):100-103.
10. Baratieri LN, Monteiro Junior S, de Albuquerque FM, Vieira LC, de Andrada MA, de Melo Filho JC. Reattachment of a tooth fragment with a "new" adhesive system: a case report. *Quintessence Int* 1994 Feb;25(2):91-96.

11. Baratieri LN, Ritter AV, Junior SM, Filho JCM. Tooth fragment reattachment: an alternative for restoration of fractured anterior teeth. *Pract Periodont Aesthet Dent* 1998 Jan-Feb;10(1):115-127.
12. Maia EA, Baratieri LN, De Andrada MA, Monteiro S Jr, de Araujo EM Jr. Tooth fragment reattachment: fundamentals of the technique and two case reports. *Quintessence Int* 2003 Feb;34(2):99-107.
13. Macedo GV, Diaz PI, De O Fernandes CA, Ritter AV. Reattachment of anterior teeth fragments: a conservative approach. *J Esthet Restor Dent* 2008;20(1):5-18.
14. Villat C, Machtou P, NaulinIfi C. Multidisciplinary approach to the immediate esthetic repair and long term treatment of an oblique crown-root fracture. *Dent Traumatol* 2004 Feb;20(1):56-60.