

Bilateral Single Rooted Mandibular Primary First Molars

HN Subhadra, Shrirang Anand Sevekar, AR Prabhakar

ABSTRACT

Studies and reports on root and canal morphology of primary teeth have been rare. This report describes the presence of an unusual developmental anomaly of a single root in both mandibular primary first molars in contrast to the standard description of two roots and three or four canals.

Keywords: Deciduous teeth, Root, Root canal, Single rooted molar.

How to cite this article: Subhadra HN, Sevekar SA, Prabhakar AR. Bilateral Single Rooted Mandibular Primary First Molars. *J Contemp Dent* 2013;3(3):151-152.

Source of support: Nil

Conflict of interest: None declared

INTRODUCTION

Human molar teeth demonstrate considerable anatomic complexities and abnormalities with respect to the number of roots and root canals. There are many reports on unusual morphology both in maxillary and mandibular permanent molars.¹⁻⁴

The standard anatomical description of primary mandibular first molar is two roots and three main canals.⁵ The shape and number of roots of a tooth are determined by the Hertwig's epithelial sheath, which bends in a horizontal plane below the amelodental junction and fuses in the center leaving an opening for the roots.⁶ Variation in root form is the result of failure of Hertwig's epithelial sheath to develop or fuse in the furcation area. These single roots previously were termed pyramidal, cuneiform, tubular, cylindrical, prismatic and conical.⁷ The condition of single rooted primary molars is very rare.

The purpose of this clinical report was to describe:

1. An unusual root and canal morphology in the mandibular primary first molar.
2. Bilateral existence of the same anomaly in the same patient.

CASE REPORT

A 6 and half-year-old female patient was referred to the Department of Pedodontics and Preventive Dentistry for continuation of further treatment needs by a general practitioner.

The child's parents gave a history of extraction of mandibular right primary second molar due to caries and pulp therapy of mandibular left primary second molar. Clinical examination revealed an early mixed dentition. Coronal anatomies of all the teeth were normal. Radiographic

evaluation to assess the quality of obturation of mandibular left molar and bone coverage over right mandibular second premolar incidentally revealed an unusual morphology associated with the mandibular primary first molars having single root (Figs 1A and B), following which an orthopantomogram was obtained, which showed the normal anatomy of rest of the teeth and no hypodontia (Fig. 2).

DISCUSSION

Ackerman et al was the first to report a case of single rooted primary molars in a 10-year-old child.⁷

This aberration has been more often reported to occur in mandibular and maxillary second permanent molars.^{1,8,9} When only one root is present in these teeth, the root canal system may present only a broad root canal, two canals that may or may not join or a C-shaped canal.¹⁰ Since in this case, teeth did not require any endodontic intervention, we were unable to study the canal pattern directly.

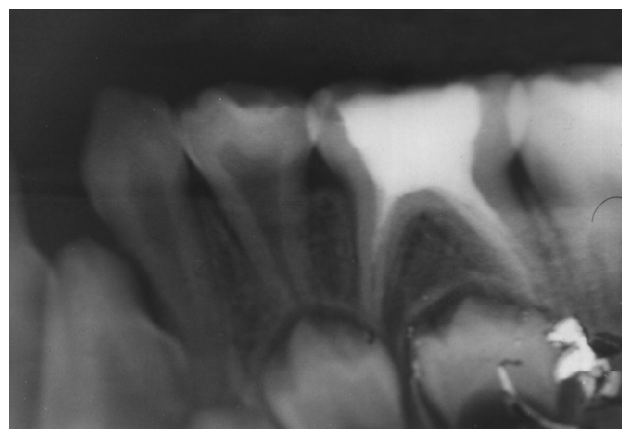


Fig. 1A: Mandibular left primary first molar

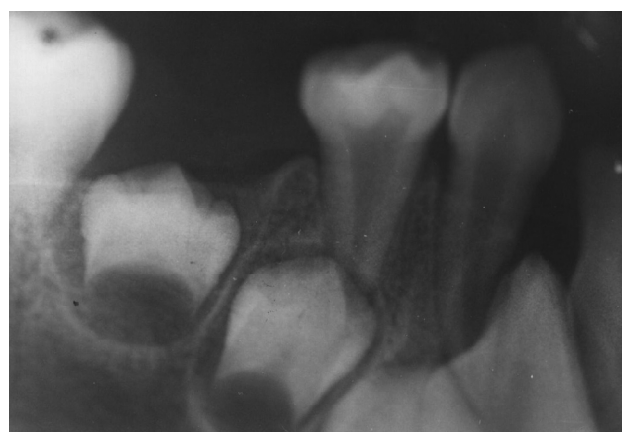

Fig. 1B: Mandibular right primary first molar

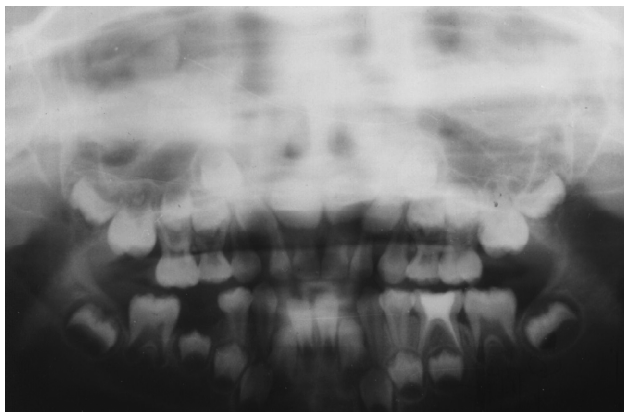

Fig. 2: Orthopantomogram

It has been suggested that single pyramid shaped roots in molars can be inherited as an autosomal dominant condition.¹¹ However, another report on single rooted molars in the primary and permanent dentition in two siblings, suggested an autosomal recessive inheritance pattern.¹²

From a clinical standpoint, when the initial radiograph shows an image with an unusual anatomy, the clinician should suspect its presence on the contralateral pair and a radiograph of the contralateral tooth should be obtained. Sabala et al stated that the more rare the aberration, the more likely that it is bilateral.⁴

Since radiographic images give a two-dimensional information about three-dimensional teeth, fewer variations in canal pattern can be detected using radiographs when compared to CT scan or *in vitro* studies using dyes and rendering the tooth transparent or by histological sectioning. However, periapical radiographs are the common diagnostic tool routinely used by many clinicians, which can provide initial clue to existence of such variations.

CONCLUSION

Single rooted permanent molars have often been reported in the literature. However, reports on single rooted primary molars are very few. This is a very unusual root anomaly associated with bilateral primary mandibular first molars. Such anomalies often tend to be bilateral.

What this case report adds?

- This is a report of an unusual root anomaly in bilateral primary mandibular first molars rarely reported in the literature.

Why this case report is important to pediatric dentists?

- This is a very unusual root anomaly of deciduous molars.
- Such anomalies often tend to be bilateral.

REFERENCES

1. Weine FS, Pasiewicz RA, Rice RT. Canal configuration of the mandibular second molar using a clinically oriented in vitro method. *J Endod* 1988;14:207-213.
2. Gulabivala K, Aung TH, Alavi A, Ng YL. Root and canal morphology of Burmese mandibular molars. *Int Endod J* 2001;34:359-370.
3. Wasti F, Shearer AC, Wilson NH. Root canal systems of the mandibular and maxillary first permanent molar teeth of South Asian Pakistanis. *Int Endod J* 2001;34:263-266.
4. Sabala CL, Benenati FW, Neas BR. Bilateral root or root canal aberrations in a dental school patient population. *J Endod* 1994;20:38-42.
5. Gutz D. Morphology of the primary dentition. In: Forrester DJ, Wangler ML, Fleming J, editors. *Pediatric dental medicine*. Philadelphia: Library of Congress Cataloging in Publication Data. 1981.p 71-80.
6. Orban B, Mueller E. The development of bifurcation of multirooted teeth. *J Am Dent Assoc* 1929;16:297-319.
7. Ackerman JL, Ackerman AL, Ackerman AB. Taurodont, pyramidal and fused molar roots associated with other anomalies in a kindred. *Am J Phys Anthropol* 1973;38:681-694.
8. Hartwell G, Bellizzi R. Clinical investigation of in vivo endodontically treated mandibular and maxillary molars. *J Endod* 1982;8:555-557.
9. Rou WJ, Dian MH, Lee IC, Huang TJ, Roan RT. Root canal system of mandibular permanent molars in a Chinese population. *J Endod* 1994;20:208 (Poster Clinic 6).
10. Fava LR, Weinfeld I, Fabri FP, Pais CR. Four second molars with single roots and single canals in the same patient. *Int Endod J* 2000;33:138-142.
11. Robbins IM, Keene HJ. Multiple morphologic dental anomalies. Report of a case. *Oral Surg Oral Med Oral Pathol* 1964;17:683-690.
12. Holan G, Chosack A. Single-rooted molars in the primary and permanent dentition in two siblings: case report. *Pediatr Dent* 1991;13:367-369.

ABOUT THE AUTHORS

HN Subhadra (Corresponding Author)

Reader, Department of Pediatric Dentistry, Bharati Vidyapeeth University Dental College and Hospital, Navi Mumbai, Maharashtra India, e-mail: drsubhadrahn@yahoo.co.in

Shrirang Anand Sevekar

Reader, Department of Pediatric Dentistry, MGM Dental College Navi Mumbai, Maharashtra, India

AR Prabhakar

Professor and Head, Department of Pediatric and Preventive Dentistry Bapuji Dental College and Hospital, Davangere, Karnataka, India